

## Abstract

Alzheimer's Disease (AD) is a neurodegenerative disorder that affects the cells in the brain which results in dementia. AD is caused by the accumulation of Amyloid Beta ( $A\beta$ ) peptides made from protein forms an accumulation in the brain that leads to plaques and tangles that affects the medial temporal lobes and neocortical structures. Early detection of AD is very important for intervention and early treatment to prevent the further progression of the disease in individuals. Magnetic Resonance Imaging (MRI) is a neuroimaging tool that can be used to help study brain changes. MRI can help to detect biomarkers that are associated with AD which could be white matter hyperintensities, hippocampal volume loss, and tau phosphorylation. Tau phosphorylation is due to cerebral atrophy which leads to neurodegeneration. The application of MRI in the early detection of AD could help in the progressive treatment and preventative methods for individuals who have AD or are at risk of developing the disease. This paper will discuss the use of neuroimaging, specifically MRI on the early detection of Alzheimer's in people which can be used in clinical settings and lead to better prevention methods.

## Introduction

Alzheimer's Disease (AD) is characterized by decline in cognition, memory loss which in turn alters behavior and interferes with activities of daily living (Breijyeh & Karaman., 2020). It is more defined as an interaction of amyloid  $\beta$  protein with glial cells and neurons, which results in neuritic plaques and neurofibrillary tangles in the cerebral cortex mostly in the medial temporal lobes and neocortical structures (Srivastava & Ahmad, 2021). AD is shown by cognitive decline, language capabilities, and loss of memory all of which can later affect behavior of the individual. Some structural symptoms would be progressive loss of neurons, neuronal network destruction and atrophy of the hippocampus (Blennow, 2006). AD symptoms are categorized based on early, moderate or late stages.

AD is a very complicated disease that could be caused by very different factors and there is no precise cause of the disease. For the early stage, the symptoms like misplacement of items, mood changes and memory loss are easily dismissed. The moderate stage is when the symptoms become more severe with difficulty in communication and spatial navigation which can interfere with personal life. In the late stage, symptoms are more severe with no remedy like inability to recognize familiar faces, physical capabilities (Khan et al., 2020)

Previous studies have also shown that atrophy and volume loss in the hippocampus are an early characteristics of AD as they can be associated with cognitive and memory decline (Eskildsen et al., 2015). Therefore, AD is the leading cause of dementia in the world; its prevalence continues to increase with the numbers doubling every 20 years. AD constitutes challenges for the healthcare system and signifies the need for strategies that could lead to early detection.

Early detection of AD is very important for the development of preventive measures and progressive treatment methods for individuals at risk. With neuroimaging tools today, MRI and

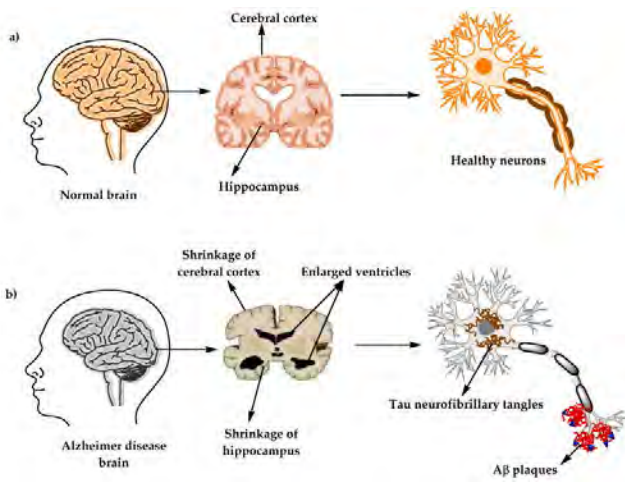
PET are the most common for their ability to detect brain abnormalities that could lead to a risk in developing AD (Mosconi et al., 2007). With these neuroimaging tools, we can be able to further prevent the development of AD in individuals.

## Alzheimer's Disease

AD is a neurodegenerative disorder and a common cause of dementia that is caused by cell death due to neuritic plaques and neurofibrillary tangles in the cerebral cortex. It is the sixth most leading cause of death in the United States and is caused by neuronal cell death which starts in the entorhinal cortex of the hippocampus. AD's etiology involves the combination of genetic predisposition, environmental factors and lifestyle choices. Even though AD is known to affect people who are older, it is necessary to know that the symptoms do not progress with age (Zvěřová, M., 2019). Many studies have shown that aging is associated with AD as they have been with approximately 90% of the cases. AD usually affects people from ages 65 and older but it is also possible that the disorder could show up earlier due to other factors like genetic mutations or even underlying health risks like heart diseases or stroke (Blennow., 2006). AD prevalence has been known to be increasing for each year and could keep increasing with the amount of cases each year.

The biomarkers for AD are mostly with blood and the structural brain changes due to the neuroimaging tool that is being used like MRI as it is more accessible and can be better used for diagnosis of the disease. (Altuna-Azkargorta & Mendioroz-Iriarte, 2021). Biomarkers are very essential for the diagnosis of the disease and also help with the use in treatment methods as well. Pathology of AD stems from the plaques and tangles in the brain due to tau phosphorylation. Another biomarker for diagnosing AD could be due to the lessening of hippocampal volume and hyperintensities of white matter in the brain (Schapiro et al., 2009). Early detection of AD would lead to better preventative methods that can be used in clinical settings for individuals.



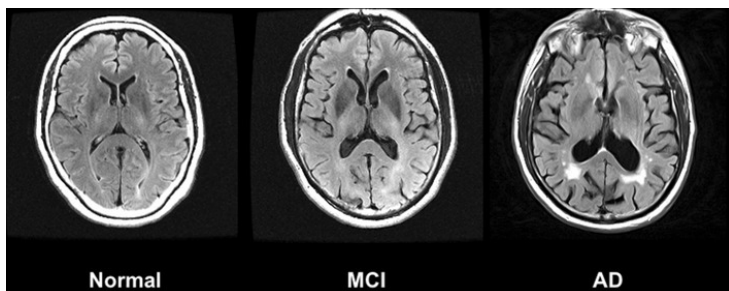


**Figure 1.** a) Structure of the brain when a healthy with the neurons and hippocampus with b) Alzheimer's showing the plaques in neurons and shrinkage of hippocampus (Breijyeh & Karaman., 2020)

## The Role of MRI in the Detection of Alzheimer's Disease

MRI, an innovative and non-invasive tool plays an important role in identifying brain changes earlier that are associated with AD leading to progressive interventions. With MRI, neurodegeneration which is present in cerebral atrophy can be captured by MRI imaging. While not being specific to cerebral atrophy, this biomarker of neurodegeneration along with neuronal injury serves as an important biomarker in the diagnosis of AD.

are also another type of biomarkers that can be used in the diagnosis of AD. Cerebral atrophy is caused by neurodegeneration which can be captured by MRI. Optimization of MRI to diagnose AD can be very valuable in the early detection of the disease. Progression of the atrophy is also later seen in the Medial Temporal Lobe (MTL) and entorhinal cortex which later results in deficits in executive functioning and memory loss for AD patients. MRI can also be used to detect white matter hyperintensities which show demyelination and axonal loss. With the use of MRI, it can play a huge role in the early detection of the disease which could lead to better treatment methods for individuals at risk before it progresses further.



**Figure 2.** Increased White Matter Hyperintensities in an Alzheimer's patient compared to a healthy normal control and a patient with Mild Cognitive Impairment (MCI) (Chandra et al., 2018).

The focus of the use of MRI can help in detecting the biomarkers associated with AD. The biomarkers associated with AD that could be detected would be cerebral atrophy, which is the loss of neurons and synapses that leads to brain

shrinkage from neurodegeneration. Atrophy and volume loss of the hippocampus also show the characteristic of AD that is associated with cognitive decline. This could spread to other regions which leads to worse progression of the disease. When the atrophy spreads to the cortical regions like frontal, parietal and temporal brain regions, the disease worsens which can be captured with MRI (Chandra et al., 2018). White matter hyperintensities is another biomarker that could be detected by MRI as they show the demyelination and loss of axons in the brain. The application of MRI in early detection of AD could make for better treatment methods that can help individuals with the disease or who could be at risk (Chandra et al., 2018).

## Challenges and Directions

While MRI can be used in the detection of AD, it also faces limitations due to sensitivity of being able to differentiate AD from either normal aging or other neurological diseases. This limitation showcases the importance for research and refinement. Another limitation would be that there could be an overlap of the imaging characteristics with other disorders that could make the results more complex. Another limitation would be the accessibility and cost that comes with using the MRI due to the equipment, which could limit its use and availability in certain settings.

MRI in the early detection of AD can be useful for the progression of treatment methods of the disease. MRI can be used to capture the alterations in brain structure like the hippocampal volume, white matter loss, and atrophy, which can give a quick insight on the development and progression of the disease before it worsens. MRI can also help clinicians and researchers be able to understand better about the brain structures affected and how they impact function so that there could be more methods for treatment which might eventually lead to a decrease in the prevalence.

## Conclusion

AD is a neurodegenerative disorder that affects millions of people worldwide and is known for being associated with aging as it mostly affects the elderly. It is caused by tangles and plaques due to tau phosphorylation which leads to neuronal cell death that affects the cerebral cortex. It is characterized by memory loss, brain structure atrophy, language capabilities and behavioral alterations. Although there is no known cause, there could also be a lot of factors that contribute to the disease which could be genetic or environmental. There are no preventive measures but there are protective measures like maintaining a healthy lifestyle and being physically active which could help.

MRI being a non-invasive tool in neuroimaging could play an important role in the detection of AD that could potentially lead to the further progress of treatment methods. There are some limitations and challenges which could come with the use of the neuroimaging tool like the cost, complexity of the detecting for the disease, and the overlap in imaging features although it can still be an innovative tool to be able to detect for the disease earlier that could lead to better methods for treatment.

## References

1. Altuna-Azkargorta, M., & Mendioroz-Iriarte, M. (2021). Blood biomarkers in Alzheimer's disease. *Neurología* (English Edition), 36(9), 704–710. <https://doi.org/10.1016/j.nrleng.2018.03.006>
2. Battineni, G., Hossain, M. A., Chintalapudi, N., Traini, E., Dhulipalla, V. R., Ramasamy, M., & Amenta, F. (2021). Improved Alzheimer's Disease Detection by MRI Using Multimodal Machine Learning Algorithms. *Diagnostics* (Basel, Switzerland), 11(11), 2103. <https://doi.org/10.3390/diagnostics11112103>
3. Blennow, K., de Leon, M. J., & Zetterberg, H. (2006). Alzheimer's disease. *The Lancet*, 368(9533), 387-403.
4. Breijyeh, Z., & Karaman, R. (2020). Comprehensive review on Alzheimer's disease: Causes and treatment. *Molecules*, 25(24), 5789. <https://doi.org/10.3390/molecules25245789>
5. Chandra, A., Dervenoulas, G., & Politis, M. (2018). Magnetic Resonance Imaging in Alzheimer's disease and mild cognitive impairment. *Journal of Neurology*, 266(6), 1293–1302. <https://doi.org/10.1007/s00415-018-9016-3>
6. Craig-Schapiro, R., Fagan, A. M., & Holtzman, D. M. (2009). Biomarkers of Alzheimer's disease. *Neurobiology of disease*, 35(2), 128-140.
7. Eskildsen, S. F., Coupé, P., Fonov, V. S., Pruessner, J. C., Collins, D. L., & Alzheimer's Disease Neuroimaging Initiative. (2015). Structural imaging biomarkers of Alzheimer's disease: predicting disease progression. *Neurobiology of aging*, 36, S23-S31.
8. Khan, S., Barve, K. H., & Kumar, M. S. (2020). Recent Advancements in Pathogenesis, Diagnostics and Treatment of Alzheimer's Disease. *Current neuropharmacology*, 18(11), 1106–1125. <https://doi.org/10.2174/1570159X18666200528142429>
9. Mosconi, L., Brys, M., Glodzik-Sobanska, L., De Santi, S., Rusinek, H., & De Leon, M. J. (2007). Early detection of Alzheimer's disease using neuroimaging. *Experimental gerontology*, 42(1-2), 129-138.
10. Srivastava, S., Ahmad, R., & Khare, S. K. (2021). Alzheimer's disease and its treatment by different approaches: A review. *European Journal of Medicinal Chemistry*, 216, 113320.
11. Zvěřová, M. (2019). Clinical aspects of Alzheimer's disease. *Clinical biochemistry*, 72, 3-6

